

NeuroReport 3, 583–586 (1992)

FOLLOWING long-term deafferentation of one upper limb in adult primates, the cortical areas corresponding to that limb become responsive to stimuli applied to the face. To explore this phenomenon, we studied some patients after upper limb amputation. In patient VQ, stimuli applied to the lower face or 7 cm above the stump evoked precisely localized referred sensations in individual digits which were often modality specific. Similarly, in another patient, WK several complete somatotopic representations of the phantom limb were found, on the face, chest and axilla, indicating the emergence of such maps in regions remote from the stump. These effects may be a direct perceptual correlate of the physiological observations of Merzenick *et al* (1984), Wall (1977) and Pons *et al* (1991).

Key words: Phantom limbs; Referred pain; Neural plasticity; Somatosensory cortex; Deafferentation; Topography; Silent synapses; Somatotopic representation; Local sign; Perception

Perceptual correlates of massive cortical reorganization

V. S. Ramachandran,^{CAA*} M. Stewart and D. C. Rogers-Ramachandran

Brain and Perception Laboratory, Psychology Department, University of California at San Diego, La Jolla, California 92093, USA;

*Experimental Psychology Department, South Parks Rd., Oxford University, Oxford, England, OX1 3UD

^{CAA*} Corresponding Author and Address

Introduction

One of the most widely accepted dogmas in neurology is the relatively stable nature of the adult mammalian brain. It is assumed, that once neural connections have been laid down in the developing foetal (or infant) brain there is very little that one can do to modify these connections in adulthood. Here we report some novel results that present a challenge to this dogma. Our experiments were motivated, in part, by the recent discovery that cortical maps are capable of a surprising degree of reorganization.^{1,2} After extensive long term (12 years) deafferentation of one upper limb in adult primates the cortical area corresponding to the limb also became responsive to stimuli applied to the lower part of the face. We wondered what the perceptual correlates of this reorganization might be:^{1,3,4} would a sensory stimulus applied to the face be perceptually mislocalized i.e., would it appear to come from the hand as well as the face? To explore this we studied localization of sensations in three patients (VQ, DW and WK).

Materials, Methods and Results

Patient VQ: Patient VQ was an intelligent alert 17 year old whose left arm was amputated 6 cm above the elbow about 4 weeks prior to our testing him.

We studied localization of touch (and light pressure) using a Q-tip that was brushed twice in rapid succession at various randomly selected points on his skin surface. His eyes were shut during the entire procedure and he was simply asked to describe any sensations that he felt and to report the perceived location of these sensations. We found that even stimuli applied to points remote from the amputation line were often systematically mislocalized to the phantom arm. Further-

more, the distribution of these points was not random⁵ but appeared to be clustered on the lower left side of the face (i.e., ipsilateral to amputation) and there was a systematic one-to-one mapping between specific regions on the face and individual digits (e.g., from the cheek to the thumb, from the philtrum to the index finger and from the chin of the fifth finger or 'pinky'). Typically, the patient reported that he simultaneously felt the Q-tip touching his face and a 'tingling' sensation in an individual digit. By repeatedly brushing the Q-tip on his face we were able to plot 'receptive fields' (or 'reference fields') for individual digits of the (phantom) left hand on his face surface (Fig. 1). The margins of these fields were remarkably sharp and stable over successive trials. Stimuli applied to other parts of the body such as the tongue, neck, shoulders, trunk, axilla and contralateral arm were never mislocalized to the phantom hand and no referred sensations were ever felt in the other (normal) hand. There was, however, one specific point on the contralateral cheek that always elicited a tingling sensation in the phantom elbow.

A second cluster of points was found about 7 cm above the amputation line. Again there was a systematic one-to-one mapping with the thumb being represented medially on the anterior surface of the arm and the 'pinky' laterally, as if to mimic the pronated position of the phantom hand. We repeated the whole procedure after one week and found an identical distribution of points suggesting that these one-to-one correspondences are stable over time. Next, we placed a drop of warm water on the patient's face. He reported that this generated a distinct feeling of warmth in his entire phantom hand. A similar feeling was also produced if we put the drop on the second 'map' 7 cms above the amputation line. No such effect occurred if we used water at room temperature. Finally, we used a

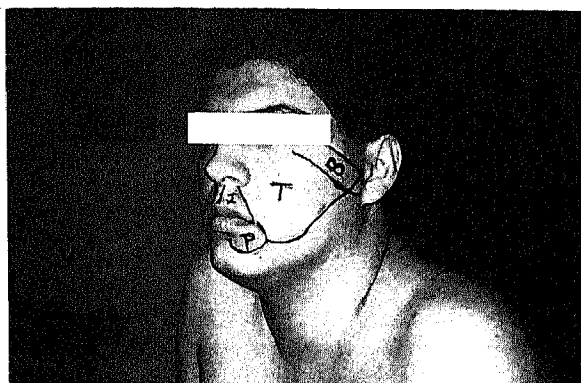


FIG. 1. Depicts regions on the left side of the face of patient VQ which elicited precisely localised referred sensations in the phantom digits. 'Reference fields', regions that evoke referred sensations, were plotted by brushing a Q-tip repeatedly on the face. The region labelled 'T' always evoked sensations in the phantom thumb, 'P' from the 'pinky', 'I' from the index finger and 'B' from the ball of the thumb. This patient was tested four weeks after amputation but it is conceivable that the reorganization occurs even earlier. (We recently studied a patient undergoing a brachial plexus block. There was some hint of referred sensations, e.g. from the face and shoulder to the 'phantom' arm but obviously this needs to be confirmed carefully.)

pin to gently prick various points on the skin surface. A pinprick delivered medially 5 cms above the stump felt like a 'pinprick' on the phantom thumb, whereas when it was delivered more laterally it was felt on the 'pinky'. These observations are of considerable interest for they suggest that even very specific sensations such as warmth or pinpricks can be mislocalized to the phantom limb in a systematic manner. Indeed, there were occasions when water trickling down the face was felt as "water trickling down the phantom hand".

Patient WK. In testing the second patient (WK) we found a very similar pattern of results although there were some interesting differences as well. This patient had a right 'forequarter' disarticulation—i.e. his entire right arm and right scapula were removed. He experienced a vivid phantom arm that was adducted at the shoulder, flexed at the elbow and pronated. We tested him exactly one year after amputation. We had WK close his eyes and rubbed the skin of his right lower jaw and cheek with one of our fingers or the tip of a ball-point pen. A representation of the entire phantom arm was found on the face with the hand being represented on the anterior lower jaw, the elbow on the angle of the jaw, and the shoulder on the temporomandibular joint. Again, as in patient VQ, there appeared to be a precise and stable point-to-point correspondence between points on the lower jaw and individual digits—the thumb being represented caudally and the 'pinky' rostrally (Fig. 2).

A second cluster of points representing the hand was found just below the axilla. Since this region is close to the line of amputation it may be analogous to the cluster of points we found in VQ's upper arm. In this region even a Q-tip was effective in eliciting referred

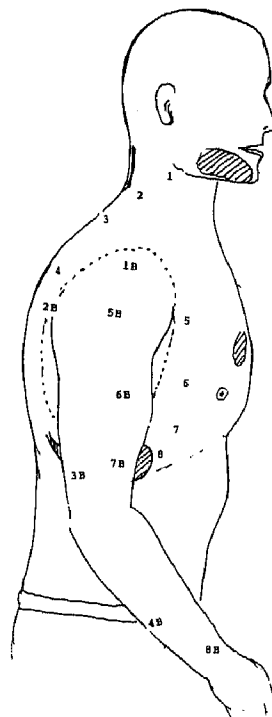


FIG. 2. Schematic illustration of patient WK showing 'reference fields'. The arm had been paralysed for three years preceding the surgery as a result of a basal cell carcinoma that had infiltrated his brachial plexus. We have drawn in the (phantom) arm to indicate the locations of referred sensations. The dotted line indicates the (presumed) line along which the arm was disarticulated. The hatched areas indicate three patches of points from which referred sensations could be elicited in the (phantom) digits and hand. These patches may be analogous to the clusters of points we observed in patient VQ.

sensations in the thumb, forefinger, pinky or palm. The 'reference field' of the thumb was surprisingly long extending posteriorly and superiorly for about 10–15 cm from this 'cluster'. Stimuli delivered to the right side of the neck, right anterior chest wall and right scapula were also mislocalized (Fig. 2). There seemed to be a crude 'topography' of sorts—points 1, 2, 3 and 4 on the right neck/shoulder region were referred to points 1B, 2B, 3B and 4B on the phantom. Similarly, points 5, 6 and 7 on the anterior chest wall were referred to the phantom upper arm and elbow (5B, 6B and 7B) and point 8 to the phantom forearm. Thus there appeared to be a continuous somatotopic representation of the entire arm extending from the clavicle to the axilla. (Point 6 was exquisitely sensitive, even displacing a single body hair at this point evoked very vivid sensations in the patient's phantom elbow.) And finally, there was also a third, less well defined somatotopic representation on the sternum with the shoulder being represented near the manubrium and the hand just medial to the nipple (hatched area of Fig. 2). If confirmed on additional patients these results would suggest that there is a tendency towards the spontaneous emergence of somatotopically organized maps even in regions remote from the line of amputation. The exact mechanism by which such maps are formed remains an interesting question for future research.

Next, we tried moving the Q-tip continuously from point 5 down past points 6 and 7. The patient exclaimed that he could feel the referred sensation moving vividly down his arm, beyond his elbow. We then tried applying warm water or delivering pinpricks at all these points but found that this was ineffective in generating either a feeling of warmth or that of a pinprick in the phantom limb. The reason for this difference between the two patients is not clear. We also extensively explored the entire body surface above the waist several times and found that stimulation of other sites was ineffective in producing any referred sensations. Note that although the total area over which referred sensations could be elicited was much greater in WK than in VQ, the pattern of distribution of those points is in fact quite similar; a cluster of points on the lower ipsilateral face and a second set of points around the amputation line. The fact that areas around the neck and chest are also effective in WK may reflect (a) the fact that the amputation was much more extensive and (b) our testing was done one year rather than four weeks after amputation.

Lastly, we also examined a 45 year old patient whose middle (3rd) finger had been amputated at the base when she was 16. Using a Q-tip, we found that touching either digit 2 or 4 at various points on the side that was adjacent to the amputated digit evoked referred sensations in roughly corresponding locations on the phantom finger. Drops of warm or cold water at these sites evoked warmth or cold in the phantom finger and when we tightly gripped and released her index finger she felt her phantom finger being tightly gripped. (Interestingly, a 'memory' of the gripping sensation persisted for 7 or 8 seconds in the phantom but not in the normal digit.) These findings are the first report of a direct perceptual correlate of the observations of Merzenich *et al.*³

Discussion

The occurrence of referred sensations in the phantom limb is in itself not new.^{6,7} It has been noted for example, that electrical stimulation of the right ear in a patient one year after amputation caused her to experience tingling paraesthesiae spreading down her phantom left hand.⁸ Indeed such sensations can be occasionally produced in normal individuals and may form the basis of 'referred pain' as well as certain therapies such as acupuncture. What is novel about our research is that we have tried to relate our findings in a systematic way to physiological results—especially the 'remapping' experiments.¹ We have suggested, for example, that the reason we see two 'clusters' of points, one on the lower face region and a second set near or around the amputation line is because the map of the hand on the sensory homunculus in the cortex and thalamus is flanked on one side by the face and the other side by the upper arm, shoulder, and axilla. If the

sensory input from the face and from around the stump were to 'invade' the cortical territory of the hand one would expect precisely this sort of clustering of points.

With regards to our experimental results themselves, what is novel can be summarized as follows: (a) The extreme rapidity of the observed changes. Patient VQ was tested four weeks after amputation. (b) The strict *one-to-one correspondence* between individual points on the lower face and points on the phantom limb. This highly precise correspondence suggests that explanations based on nonspecific 'arousal' cannot account for the phenomenon that we have observed. (c) the *non-random* distribution of points that elicit referred sensations. In both patients the points appeared clustered on the lower ipsilateral face and near or around the line of amputation. This correlates well with the physiological remapping effect described by Pons *et al.*¹ Recall, especially, that in the Penfield homunculus, the hand area is flanked on one side by the face and on the other side by the areas close to the amputation line (shoulder, upper arm). Our theory of referred sensations also makes the following curious prediction. Since the areas corresponding to the foot and the genitals are adjacent to each other in the cortex, one would expect that after amputation of the penis, (e.g. for carcinoma) stimulation of the foot should evoke sensations in the (phantom) penis. (It has not escaped our notice that this would raise interesting therapeutic possibilities.) (d) The presence of well defined 'reference fields' with sharp, stable margins. (e) The disproportionate representation of the hand in general and the digits in particular—especially the thumb. This may be a consequence of cortical magnification. (f) The fact that in patient VQ, very specific sensations such as warmth or 'pinpricks' could also be mislocalized. (Recall that warmth, even on the face was referred to the phantom hand). This suggests that referred sensations can be modality specific. It remains to be seen, however, whether the simultaneous excitation of touch receptors is required for this effect. (g) The possible existence of topography. The very fact that adjacent points on the normal skin surface map onto adjacent points in the phantom limb is in itself suggestive of topography. Also in patient WK, when we moved the Q-tip he experienced an equivalent movement of referred sensation on his phantom arm. This finding, again, is also suggestive of the occurrence at least of *patches* of topography. Cronholm⁶ also noted that in one of his patients stimulation of some points directly on the stump elicit sensations on individual digits but since the cortical remapping results were not known at that time he attributed his observations to the fact that in this patient the phantom hand itself was superimposed on the stump so that "... the location of referred sensations in the phantom hand in phenomenal space corresponds well to that of the stimulus in physical space." In our experiments, however, *multiple map-like arrangements* could be seen even in regions remote

from the phantom hand (e.g. 7 cms above the stump or on the face in patient VQ and on the axilla, neck, chest and face in WK). We therefore suggest, contrary to Cronholm, that the somatotopy we have observed is a direct consequence of 'remapping'.¹ Of course, we must bear in mind that the felt phenomenal position of the phantom hand itself may reflect cortical remapping in the proprioceptive domain (i.e. in our scheme, the phantom hand is the *effect* rather than the cause of referred sensations). (h) The occurrence of modality specific topographically organised referred sensations after digit amputation (patient DW). (i) The stability over time. In patients VQ and WK, the correspondences remained stable over intervals separated by at least a week.

Of course, these findings also raise several new questions. First, would the clustering of points and precise one-to-one correspondence be seen in all patients or only in some? Second, is the arrangement of 'reference fields' truly somatotopic and if so, what is the actual mechanism by which multiple somatotopic representations are formed? Third, how soon can the changes be observed? For example, would the changes be observed a few hours, or even immediately, after amputation? And would they occur if one were to simply block the brachial plexus using an anaesthetic?

What is the neural locus of the perceptual 'remapping' that we have observed? In trying to answer this question we have to bear three facts in mind: (1) The extent of thalamocortical axon arborizations can be quite large—up to 1 cm or more.⁹ (2) The distance between the cortical maps for the hand and face is about 1–2 cms. (3) The changes we observed are quite rapid whereas Pons *et al* recorded from their monkeys nearly 12 years after deafferentation.¹ Taken collectively, these facts imply that the effects we have shown probably arise from the unmasking of 'latent' synapses rather than actual anatomical changes such as 'sprouting'. This conclusion is consistent with the physiological observations of Wall who found rapid unmasking of synapses after partial deafferentation.⁴

Our findings also suggest a novel explanation for the very existence of phantom limbs. We would argue that the effect arises because tactile and proprioceptive input from the face and tissues surrounding the amputated limb 'takes over' the brain maps corresponding to the limb. Consequently, spontaneous discharges from these tissues would get misinterpreted as arising from the missing limb and might therefore be felt as a 'phantom' limb. This hypothesis is different from, although

not incompatible with, the view that phantom limbs arise from, a persistence of a 'neurosignature' in a 'neuromatrix'.⁸ We would argue, instead, that the effect arises from mechanisms of a much more specific nature such as remapping. One way to explain our findings would be to assume that any given point on the skin projects simultaneously to several locations, e.g. the sensory input from the face projects simultaneously to both the face and the hand neurons in the cortex (or thalamus). The unwanted input to the hand area, however, might be subject to tonic pre-synaptic inhibition (e.g. via an inhibitory interneuron) by the 'correct' axons that arrive there from the hand. If the arm is amputated on the other hand, this latent input is unmasked through disinhibition and this would lead to mislocalized sensations. What this model doesn't explain, of course, is why only one of several latent inputs gets unmasked and why you get a topographic arrangement. One can only surmise that once a given input has a slight edge, it may get progressively stabilized¹⁰ and may actively inhibit other competing inputs.

Whatever the ultimate interpretation of our findings, they present a challenge to one of the basic concepts of neuroscience, the relative stability of connections in the adult brain. The extreme rapidity (4 weeks) of the changes that we have observed suggests, instead, that the adult mammalian brain has the latent capacity for a much more rapid functional reorganization and over a much greater spatial extent than previously suspected; a capacity that could conceivably be exploited for therapeutic purposes.

References

1. Pons TP, Preston E, Garraghty AK *et al*. *Science* 252, 1857–1860 (1991).
2. Calford M. *Nature*, 352, 759–760 (1991).
3. Merzenich MM, Nelson RJ, Stryker MP *et al*. *J Comp Neurol* 224, 591–605 (1984).
4. Wall P. *Phil Trans R Soc Lond B* 278, 361–372 (1977).
5. Ramachandran VS, Stewart M and Rogers-Ramachandran DC. *Soc for Neurosciences Abstracts* (1992).
6. Cronholm B. *Acta Psychiatr Neurol Scand Suppl* 2, 1–310 (1951).
7. Howe. *Pain* 15, 101–107 (1983).
8. Melzack R. *Scientific American* 266, 120–128 (1992).
9. Jones E. Talk given at meeting on 'Neuronal group selection' held at the Rockefeller University under the auspices of the Neurosciences Research Programme (NRP) (1992).
10. Edelman GM. *Bright Air, Brilliant Fire*, Basic Books (1992).

ACKNOWLEDGEMENTS: We thank patients VQ, DW and WK for their cooperation, Drs. M. Botte and R. Abrams for referring their patients to us, F. H. C. Crick, P. Churchland, J. Allman, M. Pansa, O. Gil, R. L. Gregory, S. Cobb, and D. J. Plummer for stimulating discussions.

Received 8 May 1992;
accepted 29 May 1992